



## The post-op chest

Esophagus

---

---

---

---

---

---

### What will I gain from this video?

At the end of the video, you will know how to recognize the radiological features related to esophageal surgery.

---

---

---

---

---

---

### Complications related to surgery—EARLY

- Bleeding
- Atelectasis
- Free air
- Obstructed esophagus

---

---

---

---

---

---

**Complications related to surgery—LATE**

- Hernia/tumor recurrence
- Obstruction

---

---

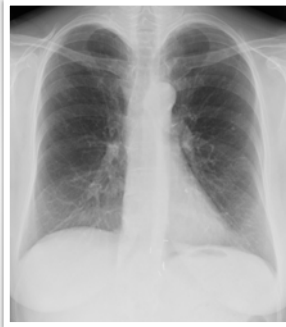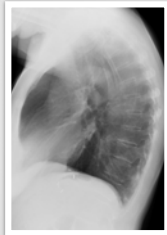
---

---

---

---

**Esophagus fundoplication**



---

---

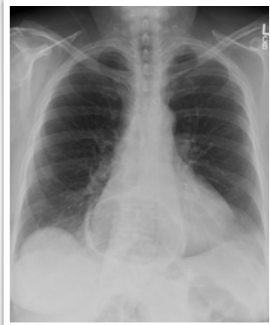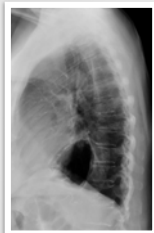---

---

---

---

**Esophagus fundoplication**



---

---

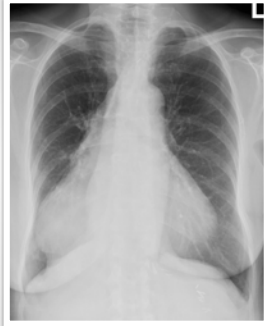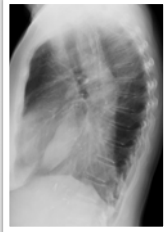---

---

---

---

**Esophagus  
esophagectomy**



---

---

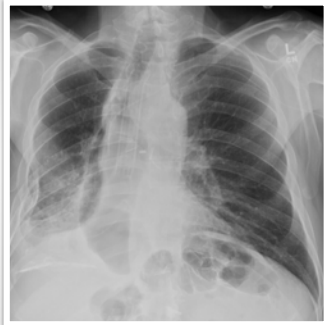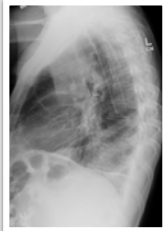---

---

---

---

**Esophagus  
stent**



---

---

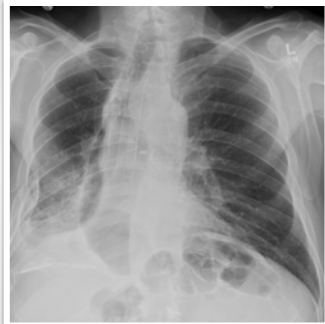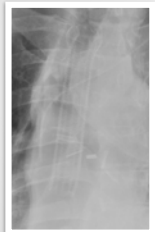---

---

---

---

**Esophagus  
stent**



---

---

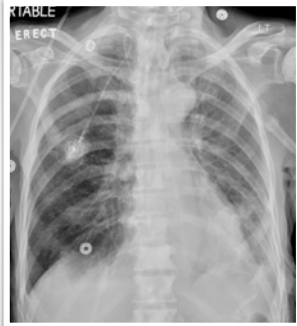---

---

---

---

**Esophagus  
stent**



---

---

---

---

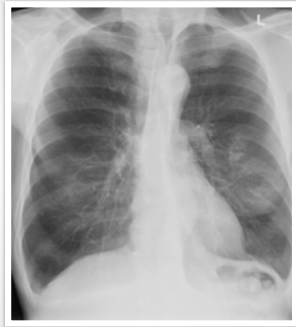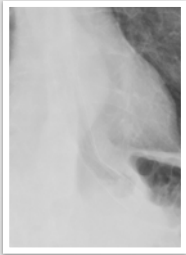---

---

---

---

**Esophagus  
stent**



---

---

---

---

---

---

---

---

Always compare to previous X-rays to identify complications.

Understand what type of surgery was performed.

Appearance will depend on type of surgery.

Early and late postoperative complications can occur.

---

---

---

---

---

---

---

---